

Case Report

Isolated Bladder Perforation in Gunshot Wound: A Case Report

 Engin Kolukcu,¹  Murat Beyhan,²  Tufan Alatli,³  Latif Mustafa Ozbek,⁴  Mehmet Ilhan Yildiz⁵

¹Department of Urology, Tokat State Hospital, Tokat, Turkey

²Department of Radiology, Tokat State Hospital, Tokat, Turkey

³Department of Emergency Medicine and Disaster Management, Gaziosmanpasa University, Tokat, Turkey

⁴Department of Urology, Iğdır State Hospital, Iğdır, Turkey

⁵Department of General Surgery, Tokat State Hospital, Tokat, Turkey

Abstract

Urinary system damage is observed in about 6-11% of cases presenting with gunshot wounds, and the bladder is most affected organ of lower urinary system. However, neighboring organ injuries mostly accompany the pathologies of bladder due to gunshot wounds. In the present study, the case of a 19 years old male patient with isolated bladder wound after being shot in left gluteal region is presented and discussed based on literature.

Keywords: Bladder, gunshot, perforation

Cite This Article: Kolukcu E, Beyhan M, Alatli T, Ozbek LM, Yildiz MI. Isolated Bladder Perforation in Gunshot Wound: A Case Report. *EJMI* 2019;3(4):336-339.

About 68-86% of bladder injuries develop due to blunt traumas, 3-14% due to penetrant traumas and 1-2% due to iatrogenic causes. Of these injuries, 45-85% are extraperitoneal, 15-55% intraperitoneal and 8-10% combined wounds.^[1] Bladder is protected by its location on the prostate gland and binding of puboprostatic ligament in inferior surface. In anterior surface, on the other hand, it is fixed to abdominal region by urachal remnant. However, it is protected by intestinal loops only in posterosuperior surface, and this is also the weakest surface with a usual perforation area. A rupture in bladder is generally accompanied by other factors such as diverticulitis, fibrosis, ulceration, over-distension, inflammation, trauma or malignity.^[2]

Depending upon the number and type of bullets, multiple organ injuries are observed in gunshot wounds as a result of high velocity and nature of human anatomy. Bladder injury occurs in about 3.6% of abdominal gunshot

wounding and 20% of penetrating hip wounds.^[3] However, isolated bladder perforation is an extremely rare situation in gunshot wounding.^[4] Gun acquisition is an increasing trend in present day societies. Therefore, there has been an increase in the frequency of urogenital pathologies demanding surgical attention due to gunshot wounding.^[5] Aim of this study was to present a case in light of literature in which isolated bladder perforation developed due to gunshot wounding.

Case Report

Nineteen years old male patient was brought to emergency clinic with a gunshot wounding. In the first physical examination, he was conscious, cooperated and oriented. Arterial tension was 115/65 mm Hg, and pulse was rhythmic with 95 beats per minute. The bullet entrance wound was

Address for correspondence: Engin Kolukcu, MD. Tokat Devlet Hastanesi, Uroloji Bolumu, Tokat, Turkey

Phone: +90 535 400 23 85 **E-mail:** drenginkolukcu@gmail.com

Submitted Date: February 02, 2019 **Accepted Date:** March 18, 2019 **Available Online Date:** October 01, 2019

©Copyright 2019 by Eurasian Journal of Medicine and Investigation - Available online at www.ejmi.org

OPEN ACCESS This work is licensed under a Creative Commons Attribution-NonCommercial 4.0 International License.



in left gluteal region and exit wound in abdominal middle line right above umbilicus. The case had no systemic condition or a surgical history. Results of laboratory analyses were as follows: hemogram: 15.1 g/dl, platelet: 292000 μ /L, INR: 1.1, AST: 20 U/l, ALT: 8 U/l, creatinine: 0.71 mg/dl, urea nitrogen: 21 mg/dl, Na: 137 mEq/l and K: 4.3 mEq/l. Radiological examination of the patient revealed bladder perforation (Fig. 1). On the other hand, no pathology was observed in intraabdominal organs (Figs. 2, 3). The patient was operated by a team of surgeons in a multidisciplinary approach, and lack of pathological findings in any intraab-

dominal organ other than bladder was confirmed. Two perforated areas were observed in bladder dome and trigone. Necrotized tissues were resected and bladder was repaired with watertight technique as two layers covering detrusor and mucosa using absorbable sutures. For bladder mucosa 4/0 vicryl suture was used, while 2/0 vicryl was used for muscles and adventitia. A drain was placed in abdominal cavity. Urinary diversion was provided 20 Fr three-way catheter. No cystectomy was required. Cystography taken on the 14th day after the operation showed the perfect repair of bladder (Fig. 4). Urethral catheter was removed. No

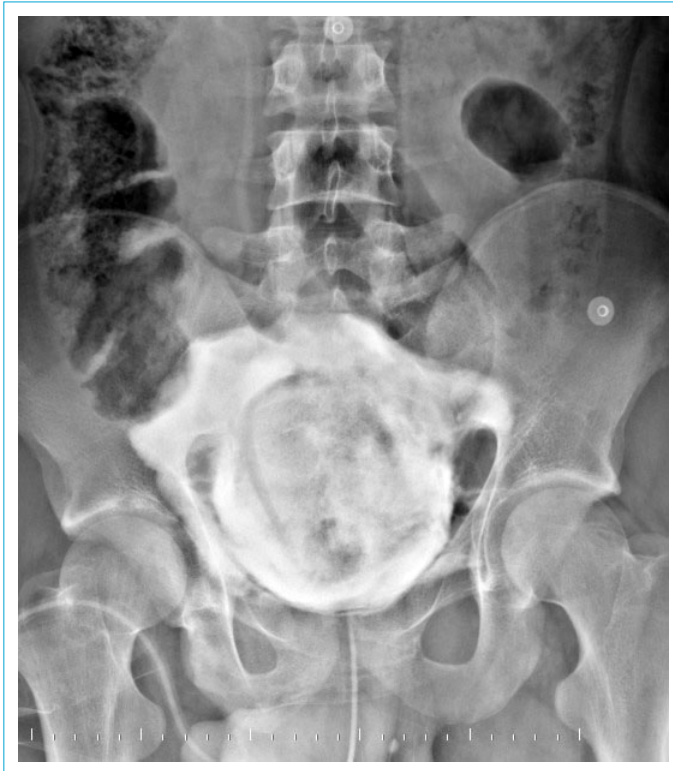

Figure 1. Image of the pelvis during retrograde cystography demonstrates contrast extravasating through wall of the bladder.

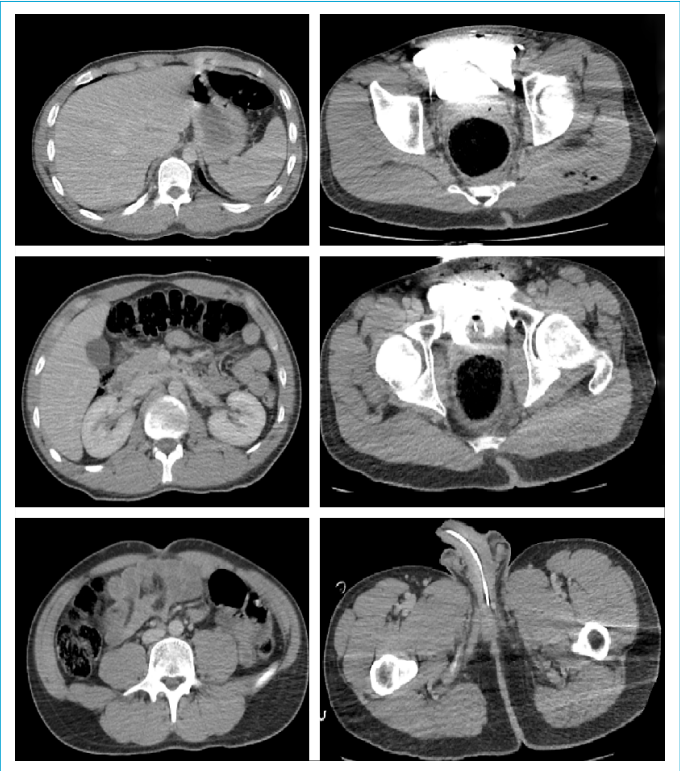


Figure 2. Axial images of the pelvis during CT cystogram demonstrate isolated bladder perforation.

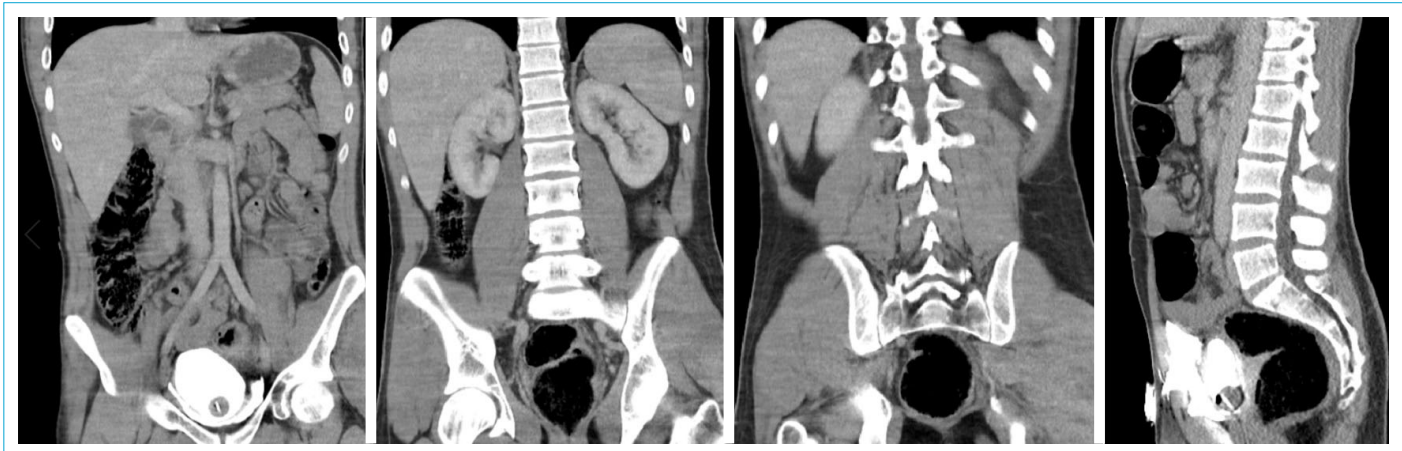

Figure 3. Coronal and sagittal images of the pelvis during CT cystogram demonstrates isolated bladder perforation.

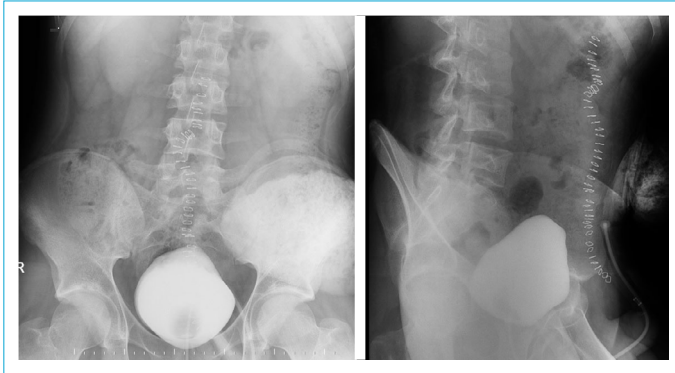


Figure 4. Retrograde cystography demonstrating normal integrity of the urinary bladder (no contrast leakage).

pathological finding was observed in clinical monitoring of the patient in routine follow-up program.

Discussion

About 6-11% of gunshot wounds involve urinary system. The organ most affected in lower urinary system is bladder.^[4] Bladder injuries must be dealt with very carefully considering the neighboring organs. In 76-95% of the gunshots involving bladder, damage is observed in neighboring organs such as colon, rectum and main vascular structures.^[1, 5] Besides, pathologies could also be observed in lower urinary organs such as ureter and posterior urethra. In their 50-case series involving gunshot wounds of lower urinary system, Cinman et al.^[4] reported gastrointestinal system injury in 80% of the cases. They also reported that 12% of the cases had both ureteric and bladder injuries, while 8% had urethral injury.

Patients may have non-specific findings such as suprapubic pain, tenderness, dysuria and hematuria in their medical histories. Evaluation of entrance and exit gunshot wounds, searching for ecchymoses throughout the body, presence of blood in urethral meatus and hematuria are extremely important during physical examination. Radiological evaluation is quite critical whenever the conditions or presenting cases allow.^[1, 4] Conventional computed tomography (CT), cystography and CT cystography are radiological methods of choice by clinicians. However, retrograde cystography is most applied, standard diagnosis method in bladder perforation.^[1] Both retrograde cystography and CT cystography are based on radiological evaluation of patients after placing a urethral catheter and filling of bladder with 300-350 cc of contrast matter. However, when a urethral injury is suspected, intactness of urethra should be checked before placing urethral catheter through retrograde urethrography.^[6, 7] In cystography, anterior-posterior and oblique x-rays should be taken, which should be repeated after bladder is emptied. Observation of contrast matter around

bladder and/or inside the abdomen is indicative for the diagnosis of a bladder injury. Sensitivity rate of the method was reported to be 85-100%.^[11] Inaccurate results are mostly caused by inappropriate conductance of the cystography. Among the leading mistakes are the taking of only posterior-anterior x-rays after the administration of contrast matter and failing to take oblique x-ray the bladder. Extravasation could be shown in x-rays of about 15% of the cases after emptying the bladder. Sensitivity and specificity of CT cystography are 95 and 100%, and it can be used instead of conventional cystography in patients for whom CT is to be made due to other reasons.^[6, 7] Unlike conventional cystography, CT cystography does not need x-ray examination after urination. Urine extravasation in the shape of a candle light is observed in extraperitoneal rupture. In intraperitoneal rupture, on the other hand, radiopaque matter is dispersed inside peritoneum. Mostly, it is not possible to see the location of rupture. Bladder is not filled with radiopaque matter so as to make bladder capacity. Also, as a result of mixing with peritoneal fluid, radiopaque matter is diluted and a ground glass appearance is observed in cystography. In the case of a small rupture, bladder could appear as compressed due to the pressure by pelvic hematoma, and manifests itself to clinicians in the form of a tear drop.^[8] Intravenous pyelography and ultrasonography are other imaging methods used to evaluate upper urinary system injury, pelvic hematoma and accumulation of fluid.^[1, 5]

The basic approach in gunshots must be exploration and repair. In this surgical intervention, vertical lower middle incision which provides a large view of abdomen and can be enlarged if needed should be preferred. In gunshot wounding, a multidisciplinary approach should be adopted and surgery team should be careful about many aspects. Necrotic tissues should be cleaned and foreign bodies must be removed. Besides, bladder wall and distal ureters should be checked. Bladder should be opened with middle line cystostomy and ureteral orifices should be examined in detail.^[3, 8] When ureteral orifices cannot be observed, intravenous indigo-carmin or methylene blue dyes could be used. In case of a wounding which involves ureteral orifices, ureteral reimplantation surgery may be necessary. Most of gunshot wounds may involve intestinal injury, and fecal diversion could be necessary.^[8-10] When vaginal or rectal injury is present, organ walls should be separated after necessary debridement and repair are conducted, and bladder should be explored. Since there are both entrance and exit gunshot wounds, it should be kept in mind that two different wound foci could exist.^[11] Technique with absorbable sutures covering detrusor and mucosa is the main method in bladder injuries.^[3, 12] Placing a transurethral Foley catheter after suture reduces catheter-linked complication risk.

Suprapubic cystostomy is generally not needed when the conditions which need long term catheterization or immobilization such as head trauma or complex orthopedic injuries do not exist. Removal of Foley catheter after the operation could be delayed up to three weeks depending upon the clinical status of the patient and severity of wounding. When no extravasation is observed in cystourethrography after the determined time period, it could be safely removed.^[3, 8]

Late diagnosed or undiagnosed intraperitoneal ruptures could lead to urine extravasation, secondary ileus, abdominal distension, peritonitis, sepsis and death. Therefore, in bladder injuries due to gunshot wounding, it is extremely important to be in a multidisciplinary approach and to make diagnosis and surgical repair as soon as possible. On the other hand, after bladder perforation patients could face some complications such as hematuria, urinary system infections, lower urinary system symptoms and fistula development due to surgical intervention. Rates of these complications are closely associated with the location and extent of the wounding. However, knowledge level, experience and skill of the surgery team are also important in these rates.^[4, 6]

In patients presenting with gunshot wounding, it is extremely important to perform careful physical examination and radiological evaluation and to consider isolated bladder perforations in differential diagnosis.

Disclosures

Informed Consent: Written informed consent was obtained from the patient for the publication of the case report and the accompanying images.

Peer-review: Externally peer-reviewed.

Conflict of Interest: None declared.

Authorship Contributions: Concept: E.K., M.B., M.I.Y.; Design: E.K., T.A., L.M.O.; Supervision: E.K., M.B., L.M.O.; Material: E.K., M.B., M.I.Y.; Data collection/or processing: E.K., M.B., T.A.; Analysis and/

or interpretation: E.K., T.A., M.B.; Literature search: E.K., M.B., L.M.O.; Writing: E.K., M.B.; Critical review: E.K., M.B., L.M.O.

References

1. Gedik A, Gedik E, Tutuş A, Kayan D, Bircan K. Künt ve penetran mesane yaralanmaları. *Turkish Journal of Urology* 2010;36:76–80.
2. Bidarmaghz B, Mizumoto R, Hendahewa R. Isolated bladder rupture in an elderly patient after blunt trauma. Case report and review *International Journal of Surgery and Medicine* 2017;3:136–9. [\[CrossRef\]](#)
3. Gomez RG, Ceballos L, Coburn M, Corriere JN Jr, Dixon CM, Lobel B, et al. Consensus statement on bladder injuries. *BJU Int* 2004;94:27–32. [\[CrossRef\]](#)
4. Cinman NM, McAninch JW, Porten SP, Myers JB, Blaschko SD, Bagga HS, et al. Gunshot wounds to the lower urinary tract: a single-institution experience. *J Trauma Acute Care Surg* 2013;74:725–30. [\[CrossRef\]](#)
5. Zümütbaş AL, Korğalı E. Gluteal Bölge Ateşli Silah Yaralanmasında İzole Mesane Perforasyonu. *Üroloji Bülteni* 2012;21:43–6.
6. Sandler CM, Goldman SM, Kawashima A. Lower urinary tract trauma. *World J Urol* 1998;16:69–75. [\[CrossRef\]](#)
7. Vaccaro JP, Brody JM. CT cystography in the evaluation of major bladder trauma. *Radiographics* 2000;20:1373–81. [\[CrossRef\]](#)
8. Sharma DM, Serafetinidis E, Sujenthiran A, Elshout PJ, Djakovic N, Gonsalves M, et al. EAU Guidelines Panel on Urological Trauma. *Eur Urol Focus* 2016;2:109–10. [\[CrossRef\]](#)
9. Deibert CM, Spencer BA. The association between operative repair of bladder injury and improved survival: results from the National Trauma Data Bank. *J Urol* 2011;186:151–5. [\[CrossRef\]](#)
10. Franko ER, Ivatury RR, Schwalb DM. Combined penetrating rectal and genitourinary injuries: a challenge in management. *J Trauma* 1993;34:347–53. [\[CrossRef\]](#)
11. Al-Azzawi IS, Koraitim MM. Lower genitourinary trauma in modern warfare: the experience from civil violence in Iraq. *Injury* 2014;45:885–9. [\[CrossRef\]](#)
12. Cordon BH, Fracchia JA, Armenakas NA. Iatrogenic nonendoscopic bladder injuries over 24 years: 127 cases at a single institution. *Urology* 2014;84:222–6. [\[CrossRef\]](#)